

# Using the RED Proportion Template to Create a Beautiful Smile

*Daniel H. Ward, DDS*

It has been said that people have to see it to believe it. Cable television shows now feature young couples searching for run-down homes they can purchase for a bargain and then transform into the house of their dreams. The properties may appear hopeless, but the realtors can often envision the potential in their own minds. They rely on cad-cam computer image programs to demonstrate to the potential buyer, the final remodeled appearance of the home. The buyers are often surprised and proceed with the project once they can visualize the potential outcome of their investments.

This is true for aesthetic dentistry as well. The dentist can often see the potential for an attractive smile but must demonstrate to the patient the potential final results. Important treatment planning decisions can be better made when the consequences of these decisions can be viewed. Only after effective visual com-

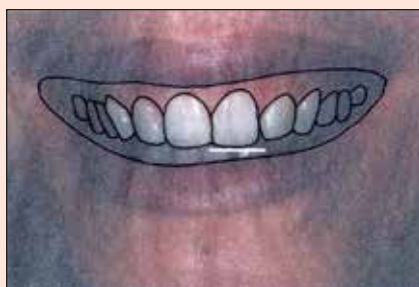munication with the patient, can informed choices be made that will ultimately satisfy the patient once the treatment is complete.

Before the era of digital photography and image manipulation, dentists had to rely on photographs of other patients either they or other dentists had treated. The patient was asked just to imagine what this smile would look like in their mouths. We all have had patients bring in smiles of models or stars they have seen in a magazine and been asked to recreate their look. Unfortunately the “look” they are seeking may be much more than just the teeth and they are frustrated when their overall appearance does not mimic the celebrity.

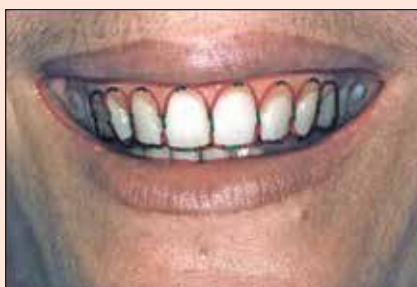In the early days of smile design the author used to take smile photographs of patients and trace out the outlines of the lips and of the teeth (Fig. 1). The new smile design was traced on a piece of

clear plastic and the patient was asked to imagine in their own minds what the smile would look like with the tracings (Fig. 2). Obviously, this is an ineffective way to adequately communicate the final results to the patient. Figure 3 shows the completed case.

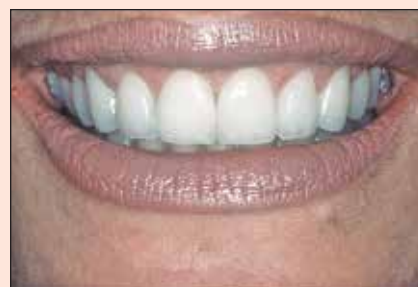Following the advent of computer imaging programs, simulations of smiles could be created. There are several types of programs that are available. Dental companies developed programs that allowed the user to outline the silhouette of the lips and to insert the teeth and gums of other patients from a smile library (Figs. 4 & 5). Though quick and easy, this technique can result in inappropriate and unrealistic expectations of the final results and dissatisfied patients (Fig. 6). A better way to simulate the potential final appearance of a smile makeover is to insert the teeth themselves under the lips and



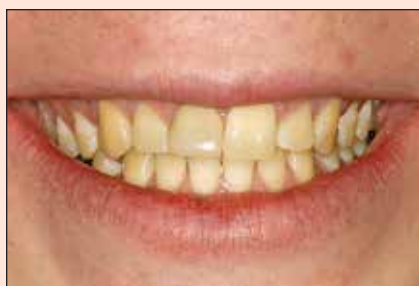**FIGURE 1**—Tracing of teeth on tissue paper



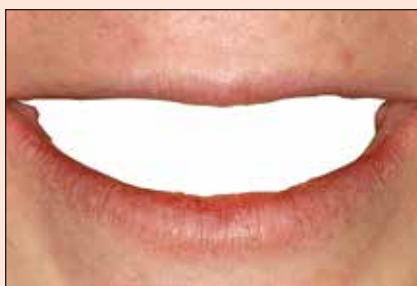**FIGURE 2**—Pre-op photo overlaid with desired tooth tracing



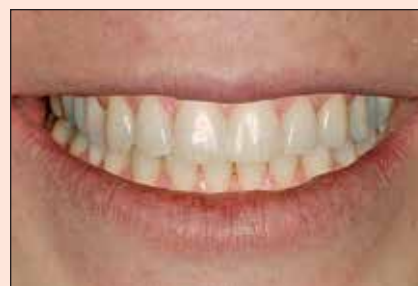**FIGURE 3**—Completed case



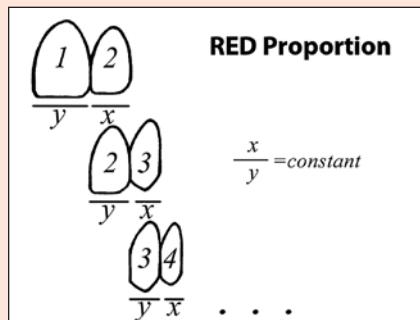
**FIGURE 4**—Smile to be imaged



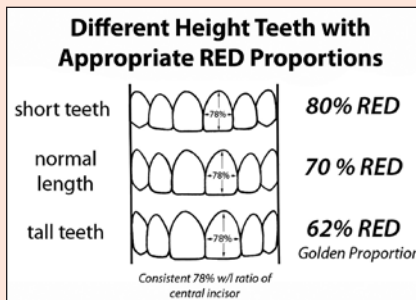
**FIGURE 5**—Smile image with area within lips removed



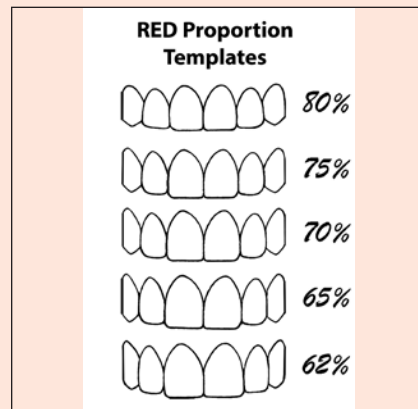
**FIGURE 6**—Smile image with area within lips replaced with teeth & gums from smile library



**FIGURE 7**—RED Proportion



**FIGURE 8**—Different RED Proportions for different tooth lengths



**FIGURE 9**—RED Template Overlay

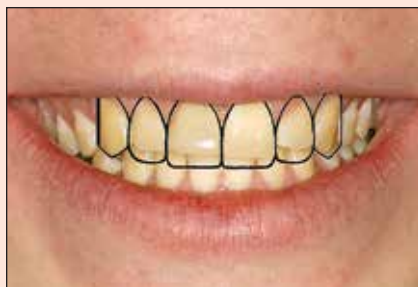over the gingiva of the patient’s photographed smile. Clinical experience and expertise should guide the dentist to determine the final potential tooth and gingival appearance.

It has been advocated that the proportions of the teeth are important to achieve smile unity.<sup>1-2</sup> Dentists should design smiles that are consistent with the size of the face and the body. Tall people generally look better with

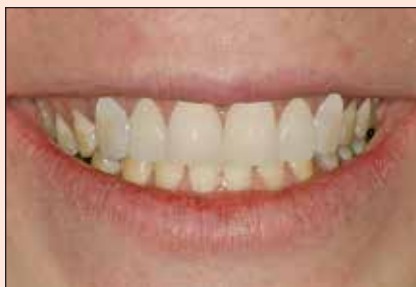tall teeth and short people are better matched with shorter teeth.<sup>3</sup> Given a fixed intercommisural width, there are an infinite number of ways that the space can be allocated.<sup>4</sup> Research has shown that dentists prefer smiles in which the width/length ratio of the maxillary central incisors are 75 to 78 percent.<sup>5</sup> A tall person would be better suited with a correspondingly wide central incisor. Less space is left for the remaining anterior teeth and therefore

they will be narrower.

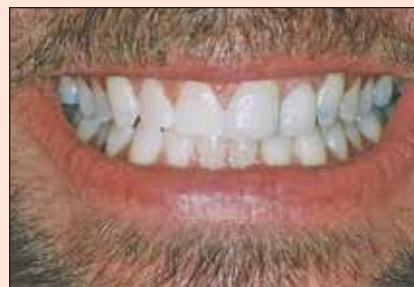The successive tooth appearance widths of the maxillary teeth as you proceed distally have been studied. A lateral incisor, which is 66 to 70 percent of the central incisor, has been observed in nature or has been preferred by dentists when evaluating smiles with normal length teeth.<sup>6-7</sup> Tall teeth with corresponding wider central incisors result in less remaining space making a smaller



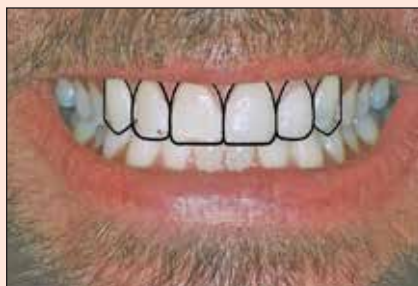**FIGURE 10**—Smile image with RED Proportion template inserted in area within lips



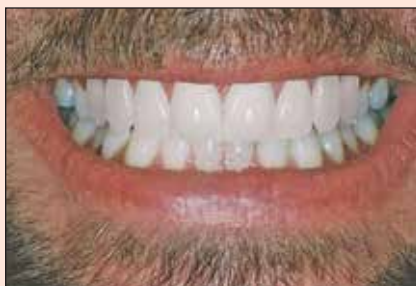**FIGURE 11**—Smile image complete using RED Proportion template



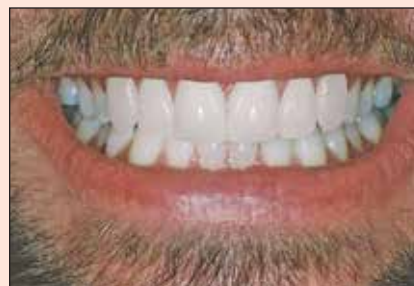**FIGURE 12**—Pre-treatment photo



**FIGURE 13**—Pre-treatment photo with RED Template overlay



**FIGURE 14**—Imaged photo for eight recommended restorations

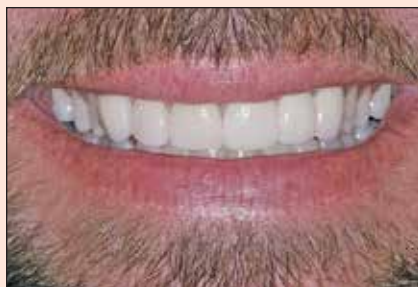

**FIGURE 15**—Re-imaged photo for six restorations

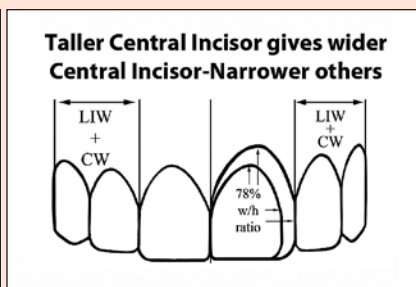
tooth width proportion necessary for the lateral incisor. The “Golden Proportion” or 62 percent RED Proportion has been demonstrated to be preferred by dentists surveyed for very tall teeth.<sup>8</sup> The RED Proportion

stand for “Recurring Esthetic Dental” Proportion which evaluates the successive tooth widths of the maxillary anterior teeth as you move distally and suggests that this proportion remain constant<sup>9</sup> (Fig. 7). In other words,

the appearance width of each tooth diminishes by the same proportion as you progress distally. This concept may be useful as a guide in designing smiles. Using this concept, short teeth result in maxillary anterior teeth



**FIGURE 16**—Completed treatment with six teeth restored



**FIGURE 17**—Taller tooth gives wider Central Incisor-narrower others

more similar in size and a larger RED Proportion (Fig. 8). The RED Proportion seeks to design smiles in harmony with the face. Alterations to the gingival levels of the teeth will affect the recommended proportions of the teeth and may allow tooth length to better coincide with body length.

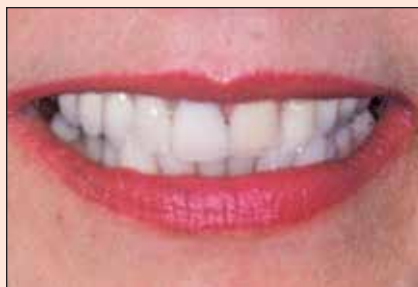A template has been created with outlines of the teeth at the preferred 78 percent width/length ratio and different RED Proportions (Fig. 9). The dentist can overlay the template on the smile photo to evaluate the different proportions. Once the appropriate proportion has been determined, the teeth can be “rubber stamped” within the outlines of the template to create the desired appearance or teeth from a proportioned smile library can be inserted (Figs. 10 & 11). This is a more realistic outcome than the earlier displayed simulation from a smile library.

This technique can be very useful in showing patients the effect of how many teeth are treated. This patient presented with a chief complaint that he did not like the gray areas in the proximal areas of the maxillary left lateral incisor (#22), which was a pontic for a Maryland Bridge. Photographs were taken and the canted incisal plane was revealed

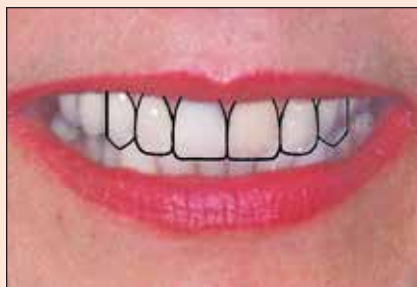(Fig. 12). It was recommended due to decay that the Maryland Bridge be replaced with an all-ceramic bridge (#21-23) and laminates be placed on the remaining maxillary anterior eight teeth (#11, 12, 13, 14, 24). The RED Proportion template was placed over the photograph (Fig. 13) and an image created showing 8 treated teeth (Fig. 14). For economic reasons the patients asked that we reimage the photo and show what six teeth would look like (Fig. 15). Based on this information the patient decided to only have six treated at this time. The final results are shown (Fig. 16).

Patients can also see the effect of cosmetic gum surgery on the final tooth proportions. According to the principles of the RED Proportion, when maxillary anterior teeth are lengthened, the central incisor should be widened to maintain the ideal 78 percent w/l ratio. The remaining anterior teeth become narrower. Figure 17 shows the effect of longer central incisors on the remaining anterior teeth width proportions. The patient presented unhappy with her smile. Photographs were taken and analyzed (Fig. 18). The appropriate RED Proportion was selected and the template placed over the photo (Fig. 19). The final recommended image was produced and approved by

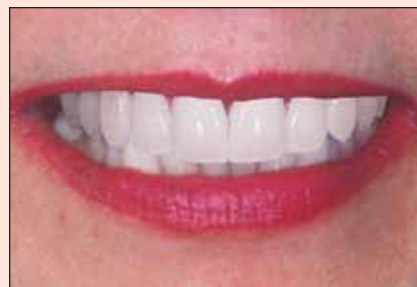



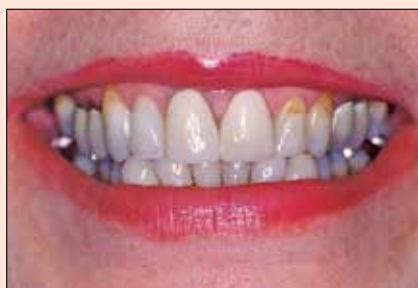**FIGURE 18**—Pre-op smile



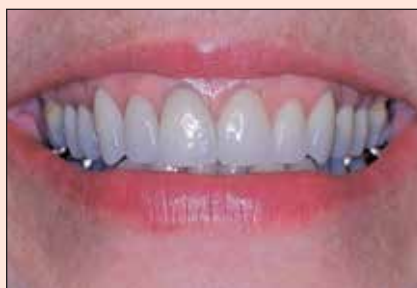**FIGURE 19**—Pre-op smile with RED Smile Template



**FIGURE 20**—Imaged smile using RED Proportion Template



**FIGURE 21**—Full smile post perio surgery



**FIGURE 22**—Completed treatment

the patient (Fig. 20). The patient was referred to the periodontist with the preferred tooth dimensions and surgery performed. The patient returned and asked that temporaries be placed over the two central incisors during healing due to the unaesthetic appear-

ance (Fig. 21). The gingiva was allowed to heal, the teeth prepared and 10 crowns placed (Fig. 22). The imaged photographs are useful in communicating with the patient and specialists. In today's world of "try in before you buy it" and "show me first" a visual simulation of the final smile appearance can be a useful for making "informed consent" deter-

minable. The imaged photographs are useful in communicating with the patient and specialists. In today's world of "try in before you buy it" and "show me first" a visual simulation of the final smile appearance can be a useful for making "informed consent" deter-

*International College of Dentists and a Fellow in the Academy of General Dentistry. Dr. Ward lectures and writes Internationally on Smile Design, Digital Dental Photography and Restorative Dentistry. He can be contacted at [dward@columbus.rr.com](mailto:dward@columbus.rr.com).*

## Callout

ance (Fig. 21). The gingiva was allowed to heal, the teeth prepared and 10 crowns placed (Fig. 22).

The RED Proportion is a valuable tool in creating smiles proportioned to the face and smile. The use of the RED Proportion template makes it easier to create imaged smiles that are re-pro-

portioned to the face and smile. The use of the RED Proportion template makes it easier to create imaged smiles that are re-pro-

minations with patients prior to beginning any active restorative treatment. **OH**

*Dr. Ward is in private practice in Columbus, Ohio. He is a Diplomate of the American Board of Aesthetic Dentistry, a Fellow of the American Society for Dental Aesthetics, a Fellow in the*

## REFERENCES

1. Lombardi RE. The principles of visual perception and their clinical application to denture esthetics. *J Prosthet Dent* 1973;29:358-382.
2. Gillen RJ, Schwartz RS, Hilton TJ, Evans DB. An analysis of selected normative tooth proportions. *Int J Prosthodont* 1994;7:410-417.
3. Boucher CO. Swenson's Complete Dentures 6th ed. St Louis. C.V. Mosby, 1970.
4. Ward DH. Using the RED Proportion to Engineer the Perfect Smile. *Dent Today* 2008;27(5):112-117.
5. Rosenstiel SF, Ward DH, Rashid RG. Dentists' Preferences of Anterior Tooth Proportion-A Web-based Study. *J Prosthodont* 2000;9:123-136.
6. Preston JD. The golden proportion revisited. *J Esthetic Dent* 1993;5:247-251.
7. Fayyad MA, Jamani KD, Aqrabawi. Geometric and Mathematical Proportions and their Relations to Maxillary Anterior Teeth. *J Contemp Dent Pract* 2006;7(5):62-70.
8. Ward DH. A Study of Dentists' Preferred Maxillary Anterior Tooth Width Proportions: Comparing the Recurring Esthetic Dental Proportion to Other Mathematical and Naturally Occurring Proportions. *J Esthet Restor Dent* 2007;19:323-336.
9. Ward DH. Proportional smile design using the RED proportion. *Dent Clin North Am* 2001;45:143-154.