CE 7

Predictable Esthetic Indirect Restorations

Daniel H. Ward, DDS
Private Practice
Columbus, Ohio

Clinical Instructor
Restorative and Prosthetic Dentistry
The Ohio State University College of Dentistry
Columbus, Ohio

Abstract: ***Patients are increasingly requesting esthetic tooth-colored restorations. Direct composite restorations have limitations based on the size of the restoration, the ability of the patient to tolerate procedures, and the ability of the dentist to provide functional restorations. The indirect composite restoration is ideal for replacing multiple failing restorations in teeth with existing restorations that are too large to be restored with direct composite restorations, yet too small to warrant the preparation for complete crowns.***

Today's health- and beauty-conscious patients are no longer satisfied with amalgam restorations in their mouths. Visible metallic restorations are unacceptable. Dentists are challenged to meet the demands of patients with durable, long-lasting, and esthetic restorations.

The direct composite restoration is the most economical esthetic alternative to an amalgam restoration. However, restoring a tooth with a direct composite can be a technique-sensitive procedure. Even small errors may result in a significant compromise to the lifetime of the restoration.

Three fundamental challenges exist when placing direct posterior composite restorations. The first challenge is polymerization shrinkage. Conventional bis-GMA resin-containing composite restorative materials shrink approximately 1% to 4% by volume on polymerization, resulting in open margins, sheared enamel rods, or fractured enamel.[1] If the shrinkage stress remains after polymerization, cusp flexure may occur, resulting in sensitive teeth during mastication.[2-4]

Attempts to control the negative consequences of shrinkage with currently available composite resins include incremental buildup, ramp curing, pulse-delay curing, soft-start curing and trans-enamel polymerization.[5-9] Incremental buildup is time-consuming and may result in voids between the layers, but it is the most universally accepted method available today to manage polymerization-shrinkage stress.[10] Initiating curing with a low light intensity that gradually increases has been demonstrated to reduce polymerization shrinkage stress in some laboratory studies, but has not been observed to be as beneficial clinically.[11] Initiating polymerization with a brief, low-intensity exposure to light and then waiting several minutes before the final, high-intensity curing has been shown in some research to reduce polymerization shrinkage stress, but this may not be a clinically practical alternative in today's busy practice environment. An initial cure from the outside of the tooth (so that the material closest to the tooth margin shrinks before the mass in the center of the tooth and releases polymerization shrinkage stress before reaching the gel state) may be helpful, but the concept has not been thoroughly proven in the laboratory.

The second challenge of placing direct composite restorations is wear. Significant advances have been made in restorative materials by using different filler particles, smaller filler particles, and a more uniform size distribution of the filler particles.[12] Most of today's composites wear 9 µm to 30 µm per year more than natural tooth structure. The loss of occlusal anatomy may result in inefficient chewing, hypereruption of the tooth, and the possible introduction of occlusal interferences. If multiple teeth have been restored with composite materials, there may eventually be a reduction of the vertical dimension of occlusion.

After proper exposure to the curing light, approximately 40% to 70% of the typical bis-GMA–based composite resin converts to polymer.[13] If this

Learning Objectives

After reading this article, the reader should be able to:

- describe the indications for indirect composite restorations.
- discuss the limitations and challenges of placing direct composite Class 2 restorations.
- describe a technique for preparing and seating indirect composite restorations.

Figure 1—Pretreatment view of multiple defective amalgams.

Figure 2—A slow-speed handpiece with a round bur was used to ensure the complete removal of decay.

Figure 3—Repreparation of teeth.

ratio could be increased, the wear rate and physical properties would increase significantly.[14-15] Reinforced microfill composite resin systems decrease the wear rate, but the material can fail from bulk fracture if placed in large increments.

The third challenge of direct composite restorations is improper interproximal contour and contact. Open interproximal contacts can result in "food traps" that allow food to accumulate at the vulnerable gingival margin. Improperly contoured or overcontoured interproximal areas can result in areas that are difficult for the patient to floss properly.

Experienced clinicians have improved their results through the use of sectional, dead-soft, and plastic matrices, prewedging, prepolymerization of composite beads, specially wedged light-curing tips, prepolymerized inserts, and other methods.[16-19] Even if adequate interproximal contact is obtained, the restoration is often overcontoured and impinges on the gingiva. Most of these techniques require experience and may not be as predictable or ideal as desired.

The challenges magnify as the restoration size required increases. Small Class 1 posterior composite restorations that involve less than 50% of the width between the buccal and lingual cusps seem to be satisfactory with direct composite restorations. The problems become more acute in larger Class 1 and Class 2 restorations. If the effects of polymerization shrinkage stress on the tooth structure and wear rates could be decreased, the amount of polymerization that occurs in composites could be increased, and clinicans were able to improve the interproximal contours, success with posterior esthetic restorations would increase.

Composite inlays and onlays provide solutions to many of the challenges of placing large posterior restorations. First, they help control the negative effects of polymerization shrinkage. Because polymerization occurred in the laboratory before the restoration is bonded to the tooth structure, the effects of cusp flexure or fracture are dramatically reduced. The 1% to 4% polymerization shrinkage that occurs during the fabrication of the restorations allows space for the thickness of the bonded resin cement. While the cement does undergo polymerization shrinkage, it is insignificant in relation to the total volume of the entire restoration. Second, because the restoration is specially treated outside the mouth, it undergoes a higher percentage of polymerization. The application of heat and/or pressure causes the polymerization to increase to approximately 90%. The resulting restoration is harder, which can be perceived intraorally during shaping procedures.[20] Third, because the interproximal areas are formed before final cementation, ideal interproximal contact and contours can be properly designed.[21]

Indications

In general, indirect composite inlays/onlays may be ideal for patients who do not want metallic restorations, and when an esthetic restoration is desired on a tooth that is deemed too large for a direct approach, yet too small for a complete crown. Indirect composite inlays/onlays are also indicated when the buccal-lingual width of the restoration exceeds 50% of the intercuspal width of the tooth, and large restorations in the molar region involve both interproximal areas of the tooth in areas with difficult access. If the dentist has difficulty routinely developing consistent interproximal contacts, an indirect procedure may be preferred. Additionally, if a patient wants maximum esthetics with a minimum of tooth preparation, or requires the esthetic replacement of multiple amalgam restorations, indirect restorations may be the best choice (Figure 1).

Preparation

Several modifications to the conventional gold inlay/onlay preparation are necessary for

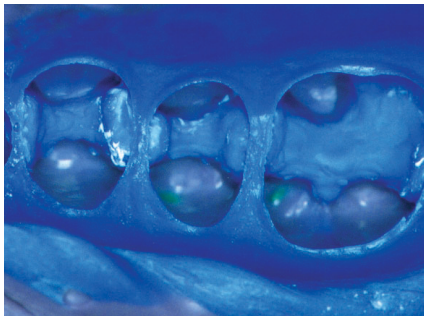

Figure 4—Final impression.

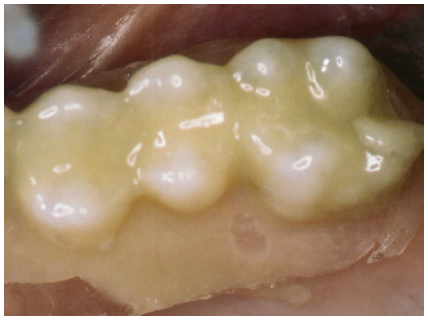

Figure 5—Autopolymerizing composite provisional material in the matrix inserted in the mouth.

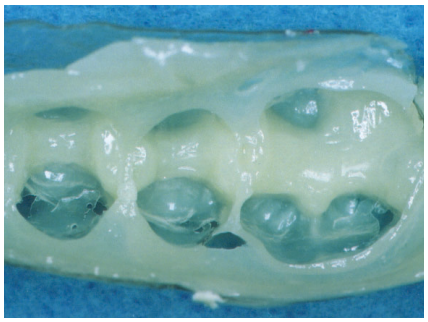

Figure 6—Provisional restoration in the matrix removed from the mouth.

Figure 7—Seated provisional restorations.

successfully placing composite inlays and onlays. The proximal walls should be more divergent, flaring 5 to 15 degrees toward the occlusal surface and resulting in a less retentive preparation. The internal line angles should be rounded. The cavosurface margins should not be beveled. The isthmus width should be a minimum of 2 mm. Adequate occlusal clearance with a depth of 1.5 mm to 2 mm is required.

The Preparation Appointment

1. The area should be anesthetized and preoperative impressions of both arches made. The casts are poured in dental stone. The shade of the desired restoration should be chosen before preparation. The existing restoration and decay should be removed quickly, which can be accomplished with little attention to outline form. This process should be as conservative as possible; tooth structure should be removed only if absolutely necessary to achieve these objectives. A round bur in a slow-speed handpiece should be used to ensure that all decay has been thoroughly removed (Figure 2).
2. If there are undercuts or if the preparation is deep, a resin-modified, glass-ionomer base material (such as Fuji II™ LC[a]) should be placed. The undercuts should be blocked out with a base before the final preparation of the teeth. This will significantly reduce the occlusal surface area and width of the preparation. More than the desired ideal depth of the preparation should be overbuilt.
3. Next, the ideal composite inlay/onlay preparation form is prepared. It is important that the walls diverge toward the occlusal to allow easy withdrawal of the restoration from the die as well as easy seating of the restoration during subsequent cementation. The preparation should be rounded, with no bevels. Finish lines should be very distinct (Figure 8). Sharp internal line angles and parallel walls should be avoided.
4. A final impression should be made using the usual fixed restoration impression material (Figure 4). Next, an occlusal registration should be obtained using a polyvinyl siloxane bite registration material.
5. The preoperative cast of the prepared tooth is separated. A vacuum former is used to fabricate a 0.02-in–thick splint. A provisional restoration is fabricated using an autopolymerizing composite resin temporary material, such as Luxatemp®[b] (Figures 5 and 6) by placing the material in the splint, seating it in the mouth for 1 minute, then removing it and allowing it to harden for 2 minutes. The provisional should be trimmed and the occlusion adjusted. It is then seated with a dual-cured, composite-resin temporary cement, such as Provilink®[c] (Figure 7).
6. The impression, bite record, opposing model, photographs, color specifications, and laboratory prescription are then sent to the dental laboratory.

Laboratory Fabrication

Tescera™[d], a new indirect, laboratory-processed, composite inlay material that improves the physical properties of the final restoration, has been recently introduced to the group of materials that are currently available (including Targis®/Vectris®[c], Artglass®[e], belleGlass™[f], Sinfony™[g], Cristobal®[h], and Sculpture®/FibreKor®[i]). This new system uses different types

[a] GC America Inc, Alsip, IL 60803; 800-323-7063
[b] Zenith/DMG, Englewood, NJ 07631; 800-662-6383
[c] BISCO Dental Products, Inc, Schaumburg, IL 60193; 800-BISDENT
[d] Ivoclar Vivadent®, Inc, Amherst, NY 14228; 800-533-6825
[e] Heraeus Kulzer, Armonk NY 10504; 914-273-8600
[f] Kerr Lab, Orange CA 92867; 800-322-6666
[g] 3M ESPE, St Paul MN 55144; 800-634-2249
[h] DENTSPLY Ceramco, Burlington, NJ 08016; 800-487-0100
[i] Brasseler USA®, Savannah, GA 31419; 800-841-4522

of composite resins for each layer. Using this system, the restoration in this case was layered using the optimal material for each layer. The initial layer was an opaque, dentin-colored hybrid material which exhibits significantly less polymerization shrinkage than other hybrid materials that are currently available.[22] The next several layers were made of a reinforced microfill composite resin. The final layer was a translucent, reinforced microfill composite that can improve the wear resistance of the surface. Each layer was pressurized before light polymerization to reduce porosity. When the restoration was totally formed, heat and an oxygen-free environment were introduced to further polymerize the resin and to remove the effects of the oxygen-inhibited layer. The result was a restoration with less porosity than other available indirect restorative materials, a hardened outer surface, a high degree of polymer conversion, and excellent wear characteristics.

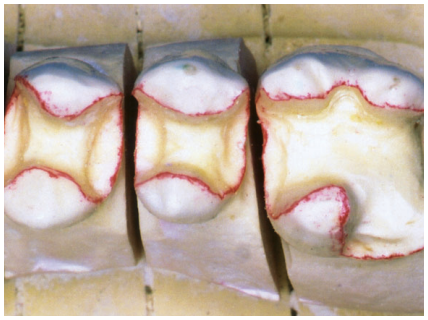

Figure 8—Dies from the laboratory.

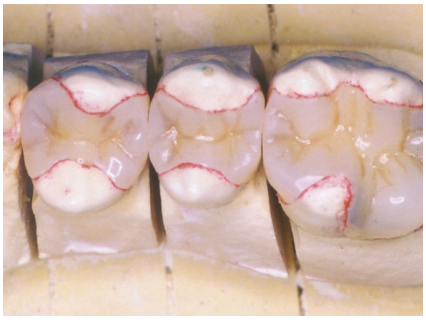

Figure 9—Restorations are checked for fit on the cast.

Figure 10—Rubber dam in place and provisionals removed.

Figure 11—Cleaning preparations with flour of pumice.

The Seating Appointment

1. The restorations should be checked for fit by evaluating the margins on the model before the seating appointment (Figures 8 and 9). The patient should be anesthetized. The rubber dam should be placed and the temporaries removed (Figure 10). The tooth preparation should be cleaned with flour of pumice and a prophy brush (Figure 11). Next, the restorations are tried in the mouth. Interproximal areas are adjusted to ensure proper seating and then the margins are evaluated. Margins should be accurate, with little discernable discrepancy between the tooth and the restoration. The internal surface of the restoration is adjusted if necessary.
2. If it is necessary to adjust the internal surface of the restoration, it should be sandblasted, with care taken to avoid the marginal areas. The restoration should be washed thoroughly and placed in an ultrasonic cleaner unit for 2 minutes, then washed, rinsed, and dried thoroughly. The composite activator should be placed on the intaglio surface of the restoration, which should subsequently be primed with the bonding agent. If necessary, retraction cord can be placed for better visualization of the margin and to control fluids. Inlays should be seated one at a time. The bonded base of the tooth should be sandblasted before seating, etched, and a dentin bonding agent should be applied to the tooth and the bonded base. A dual-cured resin cement should be mixed and applied to the inside of the inlay.
3. The restoration should be seated firmly and the margins checked with an explorer. The occlusal margin should be spot-cured with a 2-mm to 3-mm spot-curing tip for 10 seconds. Excess cement along the margins should be cleaned up, especially the difficult-to-reach interproximal and gingival margins. The interproximal areas should be flossed and light-cured for 5 seconds. A periodontal scaler should be used to remove excess flash around margins. All areas should be completely cured with a full-sized curing tip for 1 minute (Figure 12). Glycerin should be painted along all of the margins to fully polymerize the air-inhibited surface layer of the resin cement and cured for 1 minute. This process should be repeated for the other restorations (Figures 13 and 14).
4. Next, the glycerin should be washed off and the occlusion checked. A fine finishing carbide bur (such as a H379[i]) should be used

Figure 12—First inlay seated.

Figure 13—Second inlay seated.

Figure 14—All inlays seated.

Figure 15—Postoperative view of seated restorations.

around all of the occlusal margins. The occlusion should be adjusted using articulating paper. All excursive movements should be checked. The restorations should be polished using finishing points and polishing paste. Interproximal strips should be used to smooth gingival margins.

5. Each restoration should be postcured from the occlusal for 1 minute.

Conclusion

A properly fabricated and placed indirect composite inlay/onlay can provide excellent long-term results (Figure 15). Because dentists have a responsibility to provide the best for their patients, and the desire for esthetic restorations has never been greater, proper balance must be achieved between what patients want and the restorative treatment dentists know to be clinically sound.

Acknowledgment

The author would like to thank Roe Dental Laboratory, Garfield Heights, Ohio, for the fabrication of the Tescera™ restoration used in this case.

References

1. Davidson CL, Feilzer AJ. Polymerization shrinkage and polymerization shrinkage stress in polymer-based restoratives. *J Dent*. 1997:25: 435-440.
2. Onose H, Sano H, Kanto H, et al. Selected curing characteristics of light-activated composite resins. *Dent Mater*. 1985;1:48-54.
3. Davidson CL, de Gee AJ, Feilzer A. The competition between the composite-dentin bond strength and the polymerization contraction stress. *J Dent Res*. 1984;63:1396-1399.
4. Johnson GH, Gordon GE, Bales DJ. Postoperative sensitivity associated with posterior composites and amalgam restorations. *Oper Dent*. 1988;13:66-73.
5. Ernst CP, et al. Reduction of polymerization shrinkage stress and marginal microleakage using soft-start polymerization. *J Esthet Restor Dent*. 2003;15:93-1014.
6. Feilzer AJ, Dooren LH, de Gee AJ, et al. Influence of light intensity on polymerization shrinkage and integrity of restoration-cavity interface. *Eur J Oral Sci*. 1995;103:322-326.
7. Suh BI, Feng L, Wang Y, et al. The effect of the pulse-delay cure technique on residual strain in composites. *Compend Contin Educ Dent*. 1999;20(Suppl 2):4-14.
8. Belvedere P. Controlling shrinkage using TEP:trans-enamel polymerization. *Dent Today*. 1995;14:92-97.
9. Kanca J 3rd, Suh BI. Pulse activation: reducing resin-based composite contraction stresses at the enamel cavosurface margins. *Am J Dent*. 1999;12:107-112.
10. Deliperi S, Bardwell DN. An alternative method to reduce polymerization shrinkage in direct posterior composite restorations. *J Am Dent Assoc*. 2002;133:1387-1398.
11. Clincal Research Associates. Clinical effects of conventional and fast curing lights. *CRA Newsletter*. 2002;26:3.
12. Lopes GC, Ferreira RS, Baratieri LN, et al. Direct posterior resin composite restorations: new techniques and clinical possibilities. Case reports. *Quintessence Int*. 2002;33:337-346.
13. Sideridou I, Tserki V, Papanastasiou G. Effect of chemical structure on degree of conversion in light-cured dimethacrylate-based dental resins. *Biomaterials*. 2002;23:1819-1829.
14. Leinfelder KF, Wilder AD Jr, Teixeria LC. Wear rates of posterior composite resins. *J Am Dent Assoc*. 1986;112:829-833.
15. Ferracane JL. Correlation between hardness and degree of conversion during the setting reaction of unfilled dental restorative resins. *Dent Mater*. 1985;1:11-14.
16. Sturdevant CM. *The Art and Science of Operative Dentistry*. St. Louis, Mo: Mosby;1995:603.
17. Albers HF. *Tooth Colored Restoratives: Principles and Techniques*. 9th ed. Hamilton, On: BC Decker Inc; 2002:203-236.
18. Feinman RA. The plunging ball technique: Class II direct composite resins. *Pract Periodontics Aesthet Dent*. 1992;4:43-48.
19. Bowen RL, Eichmiller FC, Marjenhoff WA. Glass-ceramic inserts anticipated for 'megafilled' composite restorations. Research moves into the office. *J Am Dent Assoc*. 1991;122:71-73.
20. Kanca J 3rd. The effect of heat on the surface hardness of light activated composite resins. *Quintessence Int*. 1989;20:899-901.
21. Lowe E, Rego NA. Posterior restoration using laboratory-fabricated composite resin inlays/onlays. *Pract Periodontics Aesthet Dent*. 200;12:279-283.
22. Strassler HE, Goodman HS. Restoring posterior teeth using an innovative self-priming etchant/adhesive system with a low-shrinkage hybrid composite resin. *Restorative Quarterly*. 2002; 5(2):3-8.