PEER-REVIEWED

Conservative Universal Post and Core Buildups

Adjustable post and sleeve helps preserve root structure while maximizing strength

Daniel H. Ward, DDS

Post and core treatments are often performed on endodontically treated teeth to provide adequate crown retention. Throughout the years, lessons have been learned to improve the longevity of teeth treated in this manner. Originally, most of these restorations were supported with cast gold posts and cores. This necessitated the removal of extra tooth structure to allow for a path of insertion without undercuts, which often required an extra visit, and excessive enlargement can perforate or weaken the root.[1] Later, prefabricated metal posts were introduced to allow the post and core and crown preparation to all be performed during the same visit. With the advent of dentin bonding, the use of posts decreased in favor of bonded composite buildups. Overall, these procedures have been largely successful, but there are many variables associated with dentin bonding, and the bond strength may diminish over time.[2] Most recently, glass fiber posts were developed. These reduce the effect of show-through under all-ceramic crowns and provide an elastic modulus similar to that of dentin to reduce the incidence of catastrophic root failure.[3] Experience has shown that posts placed in badly broken-down posterior teeth and in anterior teeth, which undergo significant lateral forces, improve the rate of success.[4,5]

Conservatism has become the standard in healthcare, but especially in dentistry. Preserving as much original tooth structure as possible is paramount in endodontic and restorative treatment today.[6] Endodontists are creating the smallest access openings possible and removing the minimal amount of internal tooth structure necessary. Ideally, a post and core should use the strongest material in as much of its composition as possible while requiring minimal removal of the root structure. This creates a dilemma for restorative dentists. Using a traditional, smaller diameter post preserves more root structure but requires a larger, weaker composite core with less surface area to bond to the post. If a larger diameter

DANIEL H. WARD, DDS
Fellow
Academy of General Dentistry

Fellow
American Society for Dental Aesthetics

Private Practice
Columbus, Ohio

(1.) Close-up buccal view of broken-down tooth No. 28 following root canal therapy. **(2.)** A drill was used to remove the endodontic filling material to the ideal depth. **(3.)** Try-in of the Splendor SAP post to ensure full seating. **(4.)** Try-in of the Splendor SAP post and sleeve revealed an excellent fit. **(5.)** Extraoral application of primer to the post and sleeve. **(6.)** Buccal view of the bonded post and sleeve and core buildup.

post is used to increase strength, more root structure is removed, and a ledge may be created that can increase the risk of catastrophic root fracture.

This case report describes the use of a post and sleeve system that was recently introduced to help solve the challenges posed by the minimal removal of root structure while providing maximum strength. It is comprised of a single size drill and post that has a tapered sleeve made of the same material. The sleeve is designed to slide vertically down the post into flared canals to the depth required for best fit.

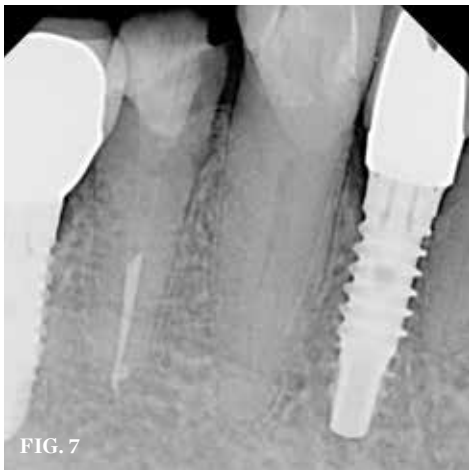
FIG. 7


FIG. 8


FIG. 9


FIG. 10

(7.) Radiograph of the bonded post and sleeve and core buildup. **(8.)** Buccal view of the completed crown preparation. **(9.)** Occlusal view of the provisional restoration. **(10.)** Occlusal view of the seated final crown.

Case Report

A patient presented with a broken-down tooth (ie, tooth No. 28) that required root canal therapy. There was a significant loss of tooth structure; therefore, a post and core treatment was deemed necessary to support a crown (Figure 1). The patient was anesthetized, and any remaining decay was excavated. After a radiograph was acquired, evaluated, and measured, a drill was used to remove approximately two-thirds of the length of the root canal filling material (Figure 2). Another radiograph was taken to confirm that the depth achieved was correct. Next, the single adjustable post system (Splendor SAP, Angelus) was tried in first without the sleeve to determine if it was fully seated (Figure 3). Then it was tried in with the sleeve and deemed to fit well (Figure 4).

This post is is among the narrowest available (0.65 mm at the apical tip, 1.0 mm at the coronal end), allowing it to fit into auxiliary canals. A sleeve is included that can be utilized, when necessary, to customize it to fit flared or overprepared canals. The sleeve significantly reduces the volume of cement required to fill the coronal area of the pulp chamber and is much stronger than composite resin, so the result is a conservative, single-visit post and core treatment that is less prone to fracture.

Following try-in, the post and sleeve were cleaned (ZirClean®, BISCO) and then thoroughly rinsed and dried. A surface primer (Z-PRIME™ Plus, BISCO) was applied to both components and allowed to dry for 2 minutes (Figure 5). Next, the root canal was acid etched (Uni-Etch® w/BAC, BISCO) for 5 seconds, washed, and partially dried using air and paper points. Chlorohexidine was then applied to the root canal for 30 seconds. After the excess moisture was removed using air and paper points, several coats of a self-curing universal dentin bonding agent (Universal Primer™, BISCO) were applied with a slender brush and rubbed for 30 seconds. These surfaces were then dried for 10 seconds with dry air. Using a self-curing adhesive primer helps to ensure that the bonding agent will cure completely when placed 6- to 12-mm deep into a canal where a curing light cannot effectively reach.

A dual-cure resin cement/buildup material (Core-Flo™ DC Lite, BISCO) was mixed and first placed on the post and sleeve. Next, a small amount of the cement was placed into the canal, and the post and sleeve were quickly inserted. The post was pushed firmly down into the canal and held while the sleeve was pushed down using a pair of cotton pliers. Additional resin was then placed to fill in and build up to the desired level, and a curing light was held over the occlusal aspect for 40 seconds (Figure 6). After the area was isolated from moisture and allowed to completely set for 3 minutes, a radiograph was taken of the post and sleeve with the buildup (Figure 7), a crown preparation was performed (Figure 8), and a provisional was fabricated for the patient (Figure 9). He returned 3 weeks later for the final crown to be seated (Figure 10).

Conclusion

With proper diagnosis, excellent root canal treatment, conservation of tooth structure, adequate substructure, a well-fitting crown, and careful attention to functional occlusion, we can provide an effective way to save teeth.

References

1. Rosenstiel S, Land M, Fujimoto *J. Contemporary Fixed Prosthodontics*, 4th ed. St Louis, MO: Mosby;2006:341.
2. Pashley DH, Tay FR, Yiu C, et al. Collagen degradation by host-derived enzymes during aging. *J Dent Res.* 2004;83(3):216-221.
3. Boksman L, Glassman G, Coelho-Santos G. Fiber posts and tooth reinforcement: evidence in the literature. Oral Health Group website. https://www.oralhealthgroup.com/features/fiber-posts-and-tooth-reinforcement-evidence-in-the-literature/. Published May 1, 2013. Accessed January 25, 2021.
4. Ferrari M, Cagidiaco MC, Grandini S, et al. Post placement affects survival of endodontically treated premolars. *J Dent Res.* 2007;86(8):729-734.
5. D'Arcangelo C, De Angelis F, Vadini M, et al. In vitro fracture resistance and deflection of pulpless teeth restored with fiber posts and prepared for veneers. *J Endod.* 2008;34(7):838-841.
6. Zogheib LV, Pereira JR, do Valle AL, et al. Fracture resistance of weakened roots restored with composite resin and glass fiber post. *Braz Dent J.* 2008;19(4):329-333.

MANUFACTURER INFORMATION

Angelus
angelusdental.com
855-346-3682